

## Solitary myofibroma associated with impacted third molar

Impacted third molar related myofibroma

Emrah Soylu<sup>1</sup>, Taha Pergel<sup>1</sup>, Yusuf Nuri Kaba<sup>1</sup>, Ahmet Emin Demirbaş<sup>1</sup>, Kemal Deniz<sup>2</sup><sup>1</sup> Department of Oral And Maxillofacial Surgery, Erciyes University Faculty of Dentistry<sup>2</sup> Department of Pathology, Erciyes University Faculty of Medicine, Kayseri, Turkey

*This case report was presented as a poster presentation in 26th International Congress of Turkish Association of Oral and Maxillofacial Surgery held in between April 28 and May 2, 2019 at Girne, Turkish Republic of Northern Cyprus.*

**Abstract**

Myofibroma (MF) is a benign proliferation of the myofibroblasts and classified as MF for solitary lesions (SMF) and MF for multicentric (MMF) lesions. These soft-tissue tumors exhibit a distinct predilection for occurring in the head and neck region while the most common oral location is the mandible. A 12-year-old male patient was referred to the Department Of Erciyes University Dentistry Faculty for the painless mass in the left posterior mandible. Clinical examination showed an expansive soft tissue mass in the retromandibular area associated with alveolar crest. An incisional biopsy was performed and SMF was confirmed, histopathologically. During the follow-up period for 24 months, no recurrence was observed.

The oral and maxillofacial region is a rare site for MF. Aggressive clinical features may be confused with malignancies and odontogenic cyst. Conservative treatment should be chosen in order to avoid aesthetic concerns due to its frequent incidence in children.

**Keywords**

Odontogenic cyst; Myofibroma; Wisdom teeth; Mix dentition; Adolescent

DOI: 10.4328/ACAM.20235 Received: 2020-06-08 Accepted: 2020-07-07 Published Online: 2020-07-18 Printed: 2020-11-01 Ann Clin Anal Med 2020;11(6):656-658

Corresponding Author: Taha Pergel, Department of Oral And Maxillofacial Surgery, Erciyes University Faculty of Dentistry, Kayseri, Turkey.

E-mail: tahapergel\_05@hotmail.com P: +90 3522076666/29175

Corresponding Author ORCID ID: <https://orcid.org/0000-0001-8154-8606>

## Introduction

Myofibroblasts (MFB) are special fibroblasts with smooth muscle-like properties with contraction. These are multifunctional cells and were first discovered by Gabbiani et al. by electron microscopy in experimental granulation tissue [1]. MFBs are involved in wound healing and tumor formation, extracellular matrix synthesis and tissue contraction. [2].

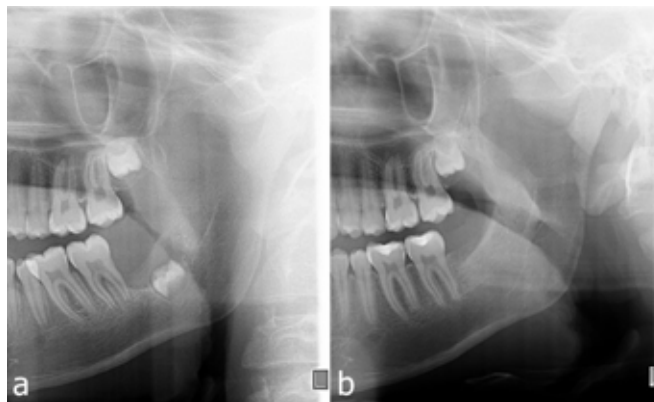
MF is a benign proliferation of the MFBs in which the disease process is classified as MF for solitary lesions (SMF) and MF for multicentric (MMF) lesions [3]. Multiple lesions in pre-pubertal children is known as infantile MF (IMF). SMFs are more common than MMF's and both have identical histopathologic features [4]. These soft-tissue tumors exhibit a distinct predilection for occurring in the head and neck region. The most common oral location is the mandible, followed by the tongue and the buccal mucosa [5, 6].

SMF usually occurs in the form of an asymptomatic, slow-growing, exo-phytic, nodular, or polypoid paramandibular mass with an intact mucosal surface. Owing to tumor size, MFs are subject to secondary masticatory trauma and ulceration. Some tumors may display a rapid growth rate, which warrants concern for a malignant or locally aggressive neoplasm. Intraosseous tumors are frequently associated with developing or erupting teeth and often demonstrate radiolucent defects that are poorly defined or expansile, or these tumors may occasionally exhibit a multiloculated appearance, evocating an odontogenic cyst or tumor [5, 7]. Treatment options vary from local excision to partial resection of the mandible. Conservative surgery should be the first treatment option and the patient should be followed for any recurrence [8]. Also, researchers have reported recurrence to be less than 10% with local excision [4]. The aim of this report is to present a rare entity of SMF mimicking an odontogenic cyst in an adolescent that is associated with an impacted tooth.

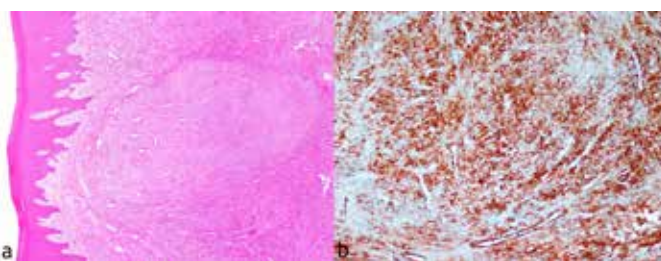
## Case Report

A 12-year-old male patient was referred to the Erciyes University, Faculty of Dentistry, Department of Oral and Maxillofacial Surgery due to the painless mass in left the posterior mandible. Clinical examination showed an expansive soft tissue mass in the retromandibular area associated with alveolar crest. The mucosa was found intact. Radiographic examination with ortopantomograph (OPG) showed a radiolucent lesion with regular margins related to impacted third molar (Figure 1a). A cone-beam dental tomography (CBDT) scan revealed a wide, unspecific homogeneous radiolucent lesion which causes erosion of the buccal cortex. An informed consent form signed by the parents of the patient, and an incisional biopsy of the lesion was performed throughout the mucosa under local anesthesia, and the specimen was sent to histopathologic and immunohistochemical analysis. Pathological examination confirmed MFB (Figure 2a, 2b). Under local anesthesia, the lesion was excised and the left mandibular impacted third molar was extracted, and wound closure was performed with 3/0 silk suture. During the operation, it was noticed that the lesion was not encapsulated and difficult to separate from the surrounding alveolar mucosa. The patient was prescribed amoxicillin+clavulanic acid 1gr, 2x1, Paracetamol 500 mg,

2x1, and mouthwash with 0.2% Chlorhexidine Digluconate. One week later, the sutures were removed, and the healing period was uneventful. Excisional biopsy was confirmed the incisional biopsy as SMF. During the follow-up period for 24 months, recurrence was not noticed, and the patient was free of complaint (Figure 1b).



**Figure 1:** a: Pre-operative OPG shows radiolucent lesion related to impacted third molar. b: Post-operative OPG at 2nd year shows uneventful healing of the lesion.



**Figure 2:** a: Light microscopic image showing fascicular proliferation of uniform myofibroblastic cells. b: Immunohistochemical staining was positive for alpha-smooth muscle actin (α-SMA) and negative for S-100, CD34, and desmin.

## Discussion

MF is a benign tumor originated from fibroblasts, most commonly a solitary lesion and, to a lesser extent, a multicenter lesion. MF is commonly seen in soft tissues, while the oral and maxillofacial region is a rare site for MF. Classification of MF is based on the radiological appearance like solitary (SMF) or multicentric (MMF). Also, MF seen in infantile is named IMF. SMF affects children more than adults, especially in the first decade of life [4, 5]. It is seen in two different clinical/radiographic forms: as an exophytic mass in the dentoalveolar segment, in a form covering the adjacent teeth, and as a mass within the bone [9]. Both variants have similar histopathological features, however, exophytic lesions show higher mitotic activity. The intraosseous type is characterized by a slowly growing intraosseous mass associated with mandible, which is usually noticed accidentally [10]. In the present case, the patient had a painless expansive swelling associated with alveolar crest intraorally and an intrabony lesion related to impacted third molar tooth germ that caused destruction of the mandibular buccal cortex.

In a radiological manner, MFs especially seen in the mandible may be confused with an odontogenic benign tumor or cyst due to the unilocular, well-circumscribed lesion. In the present case,

a painless solid mass that showed rapid growth in the retromolar region, and radiologically, a lesion with a homogeneous radiolucent appearance with prominent borders associated with embedded third molar tooth germ was detected. That's why the initial diagnosis was a dentigerous cyst because the patient was in mixed dentition and the radiological appearance of the lesion was consistent with dentigerous cyst. Differential diagnosis with dentigerous cyst should be made initially with incisional biopsy especially in adolescents in mixed dentition.

In addition, MFs must be differentiated from other benign and malign pathological entities such as leiomyoma, neurofibroma, fibrosarcoma, leiomyosarcoma, hemangiopericytoma, and desmoplastic fibroma. Hemangiopericytoma is a soft tissue sarcoma caused by pericytes in the walls of the capillaries which must be differentiated from MF to prevent wrong treatment. Neural tumors like neurofibroma are usually stained positive with S-100 protein and negative with desmin and actin. MFs are immunoreactive for vimentin and smooth muscle actin, but are stained negatively or inconsistently positive for desmin or S-100 protein. These stainings help to show the smooth muscle structure of the lesion and differentiate MF from neurofibroma and leiomyoma [11]. Immunohistochemical analysis plays a major role to establish an accurate diagnosis and for proper treatment decisions. In the present case, an incisional biopsy was performed and the diagnosis confirmed the lesion as SMF. In the literature, treatment options of the MFs vary from simple enucleation to en block resection, reconstruction plate, and bone graft combinations [7].

In the present case, considering the age of the patient and the early detection of the lesion, the lesion, and the affected tooth germ were removed by local excision and curettage before the lesion reached large dimensions.

Recurrence of the MFs is a debated issue in the literature, Daimaru et al. [12], Wolfe and Cooper [13] reported no recurrence. However, Chung and Enzinger [4] reported a 10% recurrence rate for the lesions they examined. Although these tumors are benign, most relapses are associated with incomplete removal of the lesion during surgery because it is unencapsulated. In the present case, removal of the lesion was a challenge because it was unencapsulated, which made it difficult to estimate borders and the extent of the lesion. High recurrences are more likely to occur when anatomical constraints are difficult to perform. In the present case, during the follow-up for 24 months, the patient was free of recurrence.

## Conclusion

The oral and maxillofacial region is a rare site for MF. Aggressive clinical features may be confused with malignancies and odontogenic cyst-like radiological images may be confused with odontogenic cysts and benign or malign tumors. Due to typical histological features of MFs, early diagnosis with immunohistochemical examination prior to excision of the lesion is recommended and that conservative treatment should be chosen in order to avoid aesthetic concerns due to its frequent incidence in children.

## Scientific Responsibility Statement

The authors declare that they are responsible for the article's scientific content including study design, data collection, analysis and interpretation, writing, some of the main line, or all of the preparation and scientific review of the contents and approval of the final version of the article.

## Animal and human rights statement

All procedures performed in this study were in accordance with the ethical standards of the institutional and/or national research committee and with the 1964 Helsinki declaration and its later amendments or comparable ethical standards. No animal or human studies were carried out by the authors for this article.

## Conflict of interest

None of the authors received any type of financial support that could be considered potential conflict of interest regarding the manuscript or its submission.

## References

- Gabbiani G, Ryan Majno G. Presence of modified fibroblasts in granulation tissue and their possible role in wound contraction. *Experientia*. 1971; 27(5): 549-50.
- Desmouliere A, Guyot C, Gabbiani G. The stroma reaction myofibroblast: a key player in the control of tumor cell behavior. *Intl J Dev Biol*. 2004; 48(5-6): 509-17.
- Enzinger FM, Weiss SW, Goldblum JR. *Soft tissue tumors*. St. Louis : Mosby; 1988. p. 252-68.
- Chung E, Enzinger FM. Infantile myofibromatosis. *Cancer*. 1981; 48(8): 1807-18.
- Foss R, Ellis G. Myofibromas and myofibromatosis of the oral region: a clinicopathologic analysis of 79 cases. *Oral Surg Oral Med Oral Pathol Oral Radiol Endod*. 2000; 89(1): 57-65.
- Tajima N, Shiraiishi T, Ohba S, Fujita S, Asahina I. Myofibroma of the tongue: a case suggesting autosomal dominant inheritance. *Oral Surg Oral Med Oral Pathol Oral Radiol*. 2014; 117(2): e92-6.
- Souza DP, Loureiro CCS, Rejas RAG, Sousa SOM, Raitz R. Intraosseous myofibroma simulating an odontogenic lesion. *J Oral Sci*. 2009; 51(2): 307-11.
- Allon I, Vered M, Buchner A, Dayan D. Central (intraosseous) myofibroma of the mandible: clinical, radiologic, and histopathologic features of a rare lesion. *Oral Surg Oral Med Oral Pathol Oral Radiol Endod*. 2007; 103(4): e45-53.
- Montgomery E, Speight PM, Fisher C. Myofibromas presenting in the oral cavity: a series of 9 cases. *Oral Surg Oral Med Oral Pathol Oral Radiol Endod*. 2000; 89(3): 343-8.
- Garcia-Perla A, Belmonte-Caro R, Infante-Cossio P, Muñoz-Ramos M, Francisco Esteban-Ortega F. Upper airway distress due to an oropharyngeal infantile myofibroma. *J Cranio Maxill Surg*. 2011; 40(4):e112-14.
- de Souza Azevedo R, Ramôa Pires F, Della Coletta R, Paes de Almeida O, Kowalski LP, Ajudarte Lopes M. Oral myofibromas: report of two cases and review of clinical and histopathologic differential diagnosis. *Oral Surg Oral Med Oral Pathol Oral Radiol Endod*. 2008; 105(6): e35-40.
- Daimaru Y, Hashimoto H, Enjoji M. Myofibromatosis in adults (adult counterpart of infantile myofibromatosis). *Am J Surg Pathol*. 1989; 13(10): 859-65.
- Wolfe III JT, Cooper PH. Solitary cutaneous "infantile" myofibroma in a 49-year-old woman. *Hum Pathol*. 1990; 21(5): 562-64.

## How to cite this article:

Emrah Soylu, Taha Pergel, Yusuf Nuri Kaba, Ahmet Emin Demirbaş, Kemal Deniz. Solitary myofibroma associated with impacted third molar. *Ann Clin Anal Med* 2020;11(6):656-658